

Specimen Collection Guide for Cattle or Horses with Suspected Rabies, West Nile Virus Encephalitis or Bovine Spongiform Encephalopathy (BSE)

Adapted from guidelines of the Centers of Disease Control (CDC), Washington Animal Disease Diagnostic Laboratory and Texas Veterinary Medical Diagnostic Laboratory

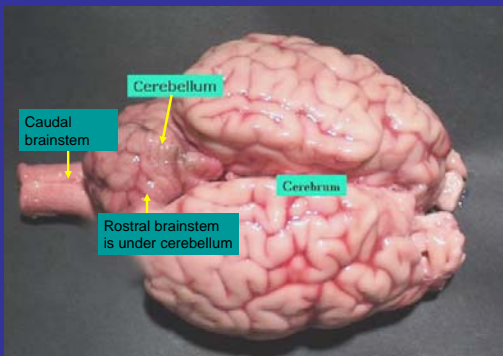


Introduction



- Rabies, West Nile encephalitis, and Bovine Spongiform encephalopathy (BSE) are uncommon but important causes of neurological illness in horses and cattle.
- Appropriate specimen collection is essential for laboratory testing. *Do not split the brain sagittally as cross sections are needed.
- These slides were developed to assist veterinarians with specimen collection and submission.
- WSU's Washington Animal Disease Diagnostic Laboratory (WADDL) in Pullman performs WNV and BSE testing; the Department of Health (DOH) does rabies testing.
- If you are not sure what specimens to submit, please call WADDL at (509) 335-9696.
- If you have rabies testing questions, please call DOH (206) 418-5500.

Review of Dorsal Brain



Rabies

- Rabies diagnosis requires fresh (NOT FIXED) brain tissue sampled from the brainstem and cerebellum
- A full cross-section of the mid-cerebellum and subjacent rostral brain stem are needed for a valid test because rabies virus antigen can localized unilaterally
- The entire cerebellum and underlying brainstem is the optimal sample
- Keep the specimen cold (refrigerated)
- Call the local public health department. They will help arrange for shipping and rabies testing
- The Department of Health Public Health Laboratory (Shoreline) does rabies testing

Rabies Sampling Site

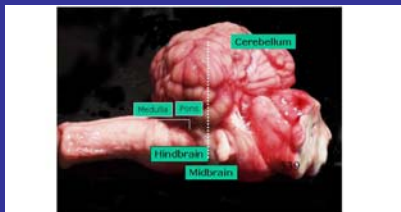

Figure 4. Lateral view of brain with cerebellum removed to show the extension of brain stem beneath the cerebellum. A rabies diagnosis should include an observation of the cut surface of a cross section of the brain stem (through the medulla, pons, or midbrain area) and the cerebellum (through each hemisphere and the vermis). For example, a cross section of the midbrain area (dashed line) would include all tissues necessary for rabies diagnosis.

West Nile Virus Encephalitis

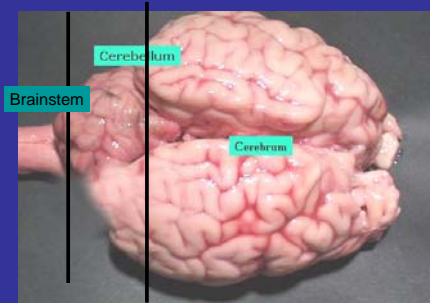
- The most common clinical signs include ataxia, weakness of hindlimbs, recumbency, muscle fasciculation and death. Many affected horses are afebrile.
- Antibody testing (serology) is appropriate when possible.
- Post mortem: Virus and lesions in horses are only found in nervous tissue; usually in the brain stem and thoracolumbar spinal cord.

West Nile Virus Diagnosis

- **Serology**
 - IgM antibody to WNV demonstrated by antibody capture ELISA during acute disease.
 - Sample: Cerebrospinal Fluid (CSF) and/or blood serum (red top tube)
- **Polymerase Chain Reaction (PCR)**
 - Detection of viral RNA in CNS tissue (postmortem)
 - Sample: Formalin-fixed or fresh /frozen whole brain (including caudal brainstem)
 - +/- spinal cord (thoracolumbar is optimal)
- **Submit to WSU / WADDL (Pullman)**
- **See diagram for taking brain samples for rabies and WNV**

WNV and Rabies Sampling

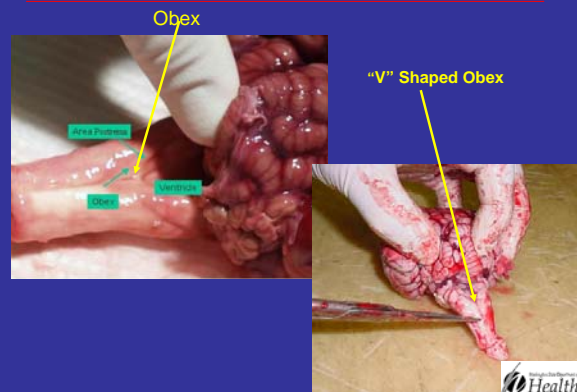
Specimen between lines for rabies testing; remainder of brain for WNV testing



Bovine Spongiform Encephalopathy

- BSE: The specimen required for BSE testing is the "V" shaped obex on the dorsal aspect of the caudal brainstem
- Take the sample from caudal to the obex (caudally) to the cerebellar peduncle (rostrally) (see attached photograph)
- BSE sampling site is caudal to rabies sampling site
- BSE and rabies testing require fresh brain (NOT FORMALIN FIXED)
- Submit BSE tests to WSU / WADDL (Pullman).
- Contact USDA-APHIS before submitting BSE sample.

BSE Specimen Collection



BSE and Rabies Specimen Collection

• Specimen between black and white lines for rabies testing.
 Specimen caudal to (behind) white line for BSE testing

